



Breast MRI: Is Faster Better?

Audrey Milon^{1,2}
 Cendos Abdel Wahab^{1,2}
 Edith Kermarrec²
 Asma Bekhouche^{1,2}
 Patrice Taourel³
 Isabelle Thomassin-Naggara^{1,2}

OBJECTIVE. Fast breast MRI protocols have the same sensitivity as conventional protocols, but their specificity is variable and can be inadequate. An ultrafast sequence provides early enhancement of lesion characteristics that optimize the characterization of the fast protocol, increasing positive predictive values without increasing time.

CONCLUSION. These new abbreviated protocols could constitute a viable screening tool both for women at high risk of breast cancer and for those at intermediate risk with high breast density.

Recently, new breast MRI protocols, called fast protocols, have been developed that obtain only one set of images after contrast material administration. These protocols take half as much time as conventional protocols but have the same sensitivity. With the increasing number of mutations for breast and ovarian cancers discovered each year and the consequently increasing number of women who required breast MRI screening, this time saving is critical to enlarge the capacity of an MRI unit to scan women at high risk of developing cancer.

This new type of protocol has been successful, and many authors have tried to develop similar approaches for other indications of breast MRI [1–5]. However, the specificity varied, mainly because of the lack of an enhancement curve study. Subsequently, an ultrafast sequence was created that provides early enhancement of lesion characteristics and optimizes the characterization of the fast protocol, increasing positive predictive value (PPV) without increasing time. By increasing throughput while reducing the cost of a breast MRI scan, these new abbreviated protocols could constitute a viable screening tool for women at high risk of breast cancer. They have also recently begun to be used for screening women at intermediate risk of breast cancer who have high breast density.

Contrast-enhanced MRI is an advanced imaging technique for diagnosing breast cancer in selected cases, with sensitivity and specificity of 87–99% and 72–81%, respec-

tively [6–8]. The standard protocol consists of unenhanced and contrast-enhanced sequences allowing examination of the morphologic and enhancement kinetic features of breast lesions [9]. When morphologic features are not suspicious, the enhancement kinetic features are useful to characterize and include lesion enhancement in early, intermediate, and late contrast-enhanced phases as depicted on time–signal intensity curves. These time–signal intensity curves are classified as persistent (type I), plateau (type II), and washout (type III), indicating benign, suspicious, and malignant lesions, respectively [10]. Lesion washout represents a specific but not very sensitive sign of malignancy: 87% of lesions with washout are malignant, but washout is found in only 57% of cancers. Even if the reported mean wash-in of benign and malignant lesions is 72% and 104%, respectively, the wide SD ranges cause a significant overlap of their enhancement features [10]. Thus, with conventional MRI protocols, washout remains one of the best feature to predict malignancy, but it requires a late acquisition after contrast material injection and a time-consuming examination. With the increasing number of women who are referred for breast MRI screening, the development of abbreviated protocols was required. The first one developed, the fast protocol, retains only the first acquisition after gadolinium injection (fast protocol) (Fig. 1). Later, the fast protocol was combined with a high temporal sequence to oversample the first minute after gadolinium injection (ul-

Keywords: abbreviated, breast, cancer, MRI

doi.org/10.2214/AJR.19.21924

Received June 28, 2019; accepted after revision September 11, 2019.

I. Thomassin-Naggara has provided remunerated lectures for GE Healthcare, Guerbet, Hologic, Canon, and Samsung and serves on advisory boards for Siemens Healthineers and Bard.

¹Sorbonne Université, Institut des Sciences du Calcul et des Données, Paris, France.

²Service d'Imagerie, Assistance Publique – Hôpitaux de Paris, Hôpital Tenon, 4 rue de la Chine, 75020, Paris, France. Address correspondence to I. Thomassin-Naggara (isabelle.thomassin@aphp.fr).

³Service d'Imagerie, Hôpital Lapeyronie, Université de Montpellier, Montpellier, France.

AJR 2020; 214:282–295

0361–803X/20/2142–282

© American Roentgen Ray Society

Abbreviated Breast MRI Protocols

trafast sequence) to reduce acquisition time while maintaining specificity.

Limits of Conventional Breast MRI

In accordance with the guidelines of the European Society of Breast Cancer Specialists, a breast MRI examination takes about 20–30 minutes to perform. Aside from being time-consuming, breast MRI is also complex to read and to archive, with usually more than 2500 images [6]. Breast MRI is now a well-established screening test for women with a high risk of breast cancer. MRI detects an additional 14.7 cancers per 1000 women with high risk who had negative findings for breast cancer on mammography and ultrasound (US) [11]. However, by definition, a screening test needs to be simple, reproducible, cost-effective and result in a low number of false-positives. Conventional breast MRI does not satisfy these criteria.

Several studies have presented the value of MRI screening for women with an intermediate risk of breast cancer including those with a history of breast cancer, biopsy-proven lobular carcinoma in situ, atypical lobular hyperplasia, or atypical ductal hyperplasia and for women with very dense breast tissue [1–5, 11–13]. However, most breast imaging groups (e.g., Society of Breast Imaging, European Society of Breast Imaging, American College of Radiology) do not recommend MRI screening for women with personal history of breast cancer or histopathologic high risk because the practice is not cost-effective [14]. This approach presents a dilemma because of the lack of accuracy of conventional screening tools. The sensitivity of mammography is much lower for women with dense breast tissue [15, 16]. Mandelson et al. [17] showed that the detection rate of breast cancer with mammography was 30% in dense breasts, compared with 80% in those without dense breasts. Breast US improves the detection of small mammographically occult breast cancers, but its overall PPV for biopsy or aspirations performed in patients with BI-RADS category 4 masses was still low at 6.5% (3/46; 95% CI, 1.7–19%) [18]. In 2015, Brem et al. [19] evaluated 3D automated breast US with screening mammography versus screening mammography alone in 112 women with dense breast tissue. Adding automated breast US to screening mammography yielded an additional 1.9 detected cancers per 1000 women screened (95% CI, 1.2–2.7; $p < 0.001$). In comparison, in 2017, Kuhl et al. [1] demonstrated that the overall

supplemental cancer detection rate of breast MRI in women at average risk of developing breast cancer (lifetime risk $< 15\%$ excluding histopathologic high-risk lesions) was 15.5 cancers per 1000 cases with a specificity of 97.1% and a PPV of 35.7%. Kuhl et al. mainly included patients with dense breasts (60.5%); most cancers (11/13, 84.6%) were detected in this population. Moreover, the interval cancer rate of women undergoing MRI screening was reduced to zero [20]. Thus, indications for breast MRI screening are likely to be extended to patients at intermediate risk of cancer with dense breast tissue. In this setting, a simplified cost-effective protocol is essential to ensure access for all eligible women.

In this review we present different studies that examined the fast protocol or ultrafast sequences whether or not they included a fast protocol for breast MRI screening or regardless of indication.

Abbreviated Breast MRI Protocol: The Groundbreaking Study

Among the different subtypes of breast cancer, MRI mainly improves the detection of invasive carcinomas and high-grade ductal carcinoma in situ (DCIS), which are well known to display initial uptake of contrast material within 90 seconds after administration. An abbreviated MRI screening protocol could therefore preferentially detect biologically significant cancers that enhance rapidly and thus do not require a lengthy scan time [21–23]. In 2014, Kuhl et al. [12] first investigated whether a fast protocol of 3 minutes total imaging, consisting of only one unenhanced and one contrast-enhanced acquisition and their derived images (first contrast-enhanced subtracted and maximum-intensity projection images), was suitable for breast MRI screening. Their prospective study included 443 women, most (82%) of whom had mildly to moderately increased risk of breast cancer, who underwent 606 MRI examinations after negative conventional breast screening imaging (mammography, US, or both). The full MRI protocol consisted of standard acquisitions: T1-weighted, T2-weighted without fat saturation, and unenhanced and contrast-enhanced T1-weighted sequences (five contrast-enhanced acquisitions) with a total imaging time of 17 minutes. The fast protocol was split into two steps. First, the readers interpreted maximum-intensity-projection (MIP) images of the first contrast-enhanced subtracted examination as positive (significant enhancement) or negative (Fig. 2). Second,

the readers interpreted the fast protocol including T1-weighted images obtained before and 1 minute after injection on native and subtracted images. The standard full diagnostic protocol was then analyzed. In this important study, 11 breast cancers were diagnosed overall, for an additional yield of 18.2 cancers per 1000 cases. Interpretation of both the fast and full protocols diagnosed all cancers with a sensitivity and negative predictive value (NPV) of 100%. Using MIP sequences only, sensitivity decreased to 91% with one cancer missed. The specificity and PPV of the fast and full protocols were equivalent (specificity, 94.3% and 93.9%; PPV, 24.4% and 23.4%; respectively). More than one-third of the BI-RADS category 3 diagnoses made on fast protocol images (20/53; 37.7%) were downgraded to definitely benign (BI-RADS category 2) on the basis of full protocol findings, obviating short-term follow-up MRI. These results support the assumption that additional T2-weighted sequences are required to optimize lesion characterization.

Confirmation With Different Fast Protocols

Breast Screening Indication

Table 1 lists studies examining use of fast protocols in breast MRI screening. First, in 2016, Harvey et al. [24] compared a fast protocol similar to that in Kuhl et al. [12] with a full protocol in 568 women. The main difference between the two studies was that the Kuhl et al. study included only women at high risk of breast cancer. Harvey et al. found no difference between the fast and full protocols in the number of cancers detected but reported a decrease in scan times of 18.8 minutes per case. Mean interpretation time was 1.55 minutes for the fast protocol compared with 6.4 minutes for the full protocol. Review of the full protocol led to a significant change in the final BI-RADS assessment in 12 of the 568 cases (2.1%), which is less than the 37.7% of cancers downgraded from BI-RADS category 3 to definitely benign in the study by Kuhl et al.

In 2017, Strahle et al. [13] evaluated an abbreviated fast protocol in 671 prospectively enrolled women with negative mammographic findings, no symptoms, no personal breast cancer history, and no prior chest radiation therapy. A standard full protocol was also performed with a scan time of 24 minutes. In this study, the optimal fast protocol required a scan time of 7.5 minutes, combining unenhanced T1-weighted and contrast-enhanced

TABLE 1: Fast Protocols for Breast Screening Showing Equal or Better Sensitivity and Specificity Than the Full Protocol

Characteristic	Kuhl et al. [12]	Harvey et al. [24]	Strahle et al. [13]	Chen et al. [4]	Panigrahi et al. [25]
No. of patients	443	568	671	356	1052
Risk of breast cancer	Mild and moderate (82%)	High	Various	Various	High
Mean age (y)	54.2	53.2	55.7	48.2	53.1
No. of lesions	177	29	17	67	46
No. of cancers	11	7	7	14	14
No. (%) of DCIS ^a	4 (36.4)	2 (28.6)	3 (43)	4 (28.6)	2 (14.3)
Mean size of cancers (mm)	8.4	—	—	12	10.7
T2-weighted sequence included					
Abbreviated protocol	No	No	Yes	No	No
Full protocol	Yes	Yes	Yes	Yes	Yes
Sensitivity (%)					
Abbreviated protocol	100	100	100	92.9	81.8
Full protocol	100	100	100	100	81.8
Specificity (%)					
Abbreviated protocol	94.3	—	—	86.5	97.2
Full protocol	93.9	—	—	96.8	97.4
Negative predictive value (%)					
Abbreviated protocol	100	100	100	99.7	—
Full protocol	100	100	100	100	—
Positive predictive value (%)					
Abbreviated protocol	24.4	—	41.2	22	—
Full protocol	23.4	—	—	56	—
Acquisition time					
Abbreviated protocol	3 min	4 min 24 s	7 min 30 s	10 min 24 s	3 min
Full protocol	17 min	23 min 12 s	24 min	32 min	24 min
Reading time					
Abbreviated protocol	28 s	1 min 33 s	—	37 s	2.4 min
Full protocol	—	6 min 24 s	—	3 min	6.6 min
Additional cancer detection rate	18.2/1000	—	16.3/1000	39/1000	13.3/1000

Note—Dash (—) indicates value not reported. DCIS = ductal carcinoma in situ.

^aNumbers in parentheses are percentages of the total number of cancers that were DCIS lesions.

T1-weighted (at 1.5 min), T2-weighted, and T1-weighted (at 6 min) sequences, which allowed standard kinetic curve calculation. The full breast MRI protocol detected 452 lesions not visible on mammography, including 17 suspicious lesions recommended for biopsy in women with dense breasts. Of these, seven (PPV, 41.2%) were malignant; all seven would have been identified on images obtained using the fast protocol. Overall, the incremental cancer detection rate among the 367 women with dense breasts was 16.3 cancers per 1000 cases.

In the same year, Chen et al. [4] evaluated the performance of a fast protocol (contrast-enhanced subtracted image and MIP)

in a retrospective study that screened 356 women with dense breast tissue who had negative mammographic and US examinations. Fourteen additional cancers were detected, resulting in an additional cancer detection rate of 39 cancers per 1000 cases. This rate is considerably higher than that in the Strahle et al. [13] study (16.3/1000) and may have resulted from the Chen et al. study focusing on women with dense breast tissue, for whom mammographic screening is known to be less efficient. The sensitivity and NPV of the fast protocol were equivalent to those of the full protocol: 92.9% versus 100% and 99.7% versus 100%, respectively. However, the specificity and PPV of the fast

protocol were significantly lower than for the full protocol: 86.5% versus 96.8% and 22% versus 56%, respectively.

Also in 2017, Panigrahi et al. [25] prospectively evaluated the performances of a fast protocol consisting of unenhanced and contrast-enhanced T1-weighted subtracted (and derived MIP) images on 746 women at high risk of breast cancer. The abbreviated protocol detected all 14 cancers (including two DCIS lesions) with equivalent reported sensitivity and specificity for the abbreviated and full protocol, respectively: 81.8% versus 81.8% and 97.2% versus 97.2% and 97.4%. They also reported high BI-RADS assessment agreement (96.6%) between the abbrev-

Abbreviated Breast MRI Protocols

TABLE 2: Selected Results From Four Studies of Fast Protocols in Nonscreening Populations

Characteristic	Mango et al. [26]	Heacock et al. [21]	Moschetta et al. [27]	Oldrini et al. [28]
Indication for MRI	Preoperative staging	Preoperative staging	Various	Various
No. of patients	100	107	470	70
Mean age (y)	52	—	53.2	53
No. of lesions	100	107	185	106
No. of cancers	100 (100)	107 (100)	75 (40)	58 (54.7)
No. (%) of DCIS ^a	23 (23)	23 (21.5)	0 (0)	8 (13.8)
Mean size of cancers (mm)	22	19	—	23
T2-weighted sequence included				
Abbreviated protocol	No	Yes	Yes	Yes
Full protocol	—	—	—	—
Sensitivity (%)				
Abbreviated protocol	96	100	89	93.1
Full protocol	—	—	92	93.1
Specificity (%)	—			
Abbreviated protocol	—	—	91	60.4
Full protocol	—	—	92	60.4
Negative predictive value (%)	—			
Abbreviated protocol	—	—	98	87.9
Full protocol	—	—	98	87.9
Positive predictive value (%)				
Abbreviated protocol	—	—	64	74
Full protocol	—	—	68	74
Diagnostic accuracy				
Abbreviated protocol	—	—	91	78.3
Full protocol	—	—	91	78.3
Acquisition time (min)				
Abbreviated protocol	12.5	12	10	5.8
Full protocol	35	—	16.4	15
Reading time				
Abbreviated protocol	44 s	—	2 min	—
Full protocol	—	—	6 ± 3.2 min	—
<i>p</i>	—	—	0.001	<0.05

Note—Dash (—) indicates value not reported. DCIS = ductal carcinoma in situ.

^aNumbers in parentheses are percentages of the total number of cancers that were DCIS lesions.

viated protocol and the subsequent review of the full protocol.

Thus, using MRI with abbreviated protocol as a screening test, additional cancer detection rates ranged from 13.3/1000 to 39/1000, with the latter in a subset of women with dense breasts. Regarding specificity, the results from the studies by Kuhl et al. [1] and Chen et al. [4] (94.4% and 85.6%, respectively) must be carefully interpreted, because BI-RADS category lesions were considered as negative cases in these two screening studies [6].

Nonscreening Populations

Table 2 summarizes selected results from studies of fast protocols in nonscreening populations. In 2015, Mango et al. [26] evaluated the ability of a fast breast MRI protocol consisting of an unenhanced T1-weighted sequence and a single early contrast-enhanced T1-weighted fat-saturated sequence (total imaging time, 12.5 min) to detect breast carcinoma in 100 consecutive women with biopsy-proven unifocal breast carcinoma undergoing breast MRI examinations. All 100

cancers were visualized by at least one of the four readers on the initial reading of the fast protocol images, and 92% of the cancers were visualized by all four readers. Sensitivity was 96% for cancers detected by at least one of the four radiologists.

In 2016, Heacock et al. [21] proposed a similar design to evaluate the use of a fast MRI protocol to detect cancer in a population of 107 women with biopsy-proven unifocal breast cancer. The protocol consisted of fat-saturated T2-weighted and

fat-saturated unenhanced and contrast-enhanced T1-weighted images with a total imaging time of 12 minutes. The mean percentage detection for the fast protocol was 99.4%, which was similar to that found in the study by Mango et al. [26]. Heacock et al. also evaluated the initial enhancement ratio (IER), defined as the signal-intensity increase between a first (unenhanced) and second (first dynamic contrast-enhanced [DCE]) MRI series, as a predictive factor for malignancy and grade of malignancy. The IER was positively associated with increasing tumor grade ($p = 0.031$) and invasive disease ($p = 0.002$), which shows the importance of early enhancement parameters.

In 2016, Moschetta et al. [27] compared a standard MRI protocol with an abbreviated fast MRI protocol combining STIR turbo spin-echo T2-weighted sequences, an unenhanced fat-saturated T1-weighted sequence, and a single intermediate contrast-enhanced fat-saturated T1-weighted sequence (3 min after contrast injection) with the corresponding subtracted series. They included 470 patients undergoing breast MRI for screening, problem solving, or preoperative staging. In 177 patients (37.7%), the MRI sequences detected 185 breast lesions and 75 cancers (16%). The full protocol had sensitivity, specificity, diagnostic accuracy, PPV, and NPV of 92%, 92%, 92%, 68%, and 98%, respectively; corresponding values for the fast protocol were 89%, 91%, 91%, 64%, and 98%, respectively, with no statistically significant difference ($p < 0.001$). The false-negative cases were eight mucinous and lobular carcinomas with high signal intensity on the T2-weighted images and mild enhancement mimicking benign lesions.

In 2017, Oldrini et al. [28] compared a fast protocol to a full protocol for distinguishing benign from malignant lesions in a population of women regardless of the indication for breast MRI, similar to what was done in the study by Moschetta et al. [27]. In this study of 106 patients (58 cancers), the diagnostic performance of the fast protocol (T2-weighted and T1-weighted with fat saturation on unenhanced and contrast-enhanced sequences) was significantly better than that of the full protocol (sensitivity, 93.1%; specificity, 60.4%; NPV, 87.9%; PPV, 74%; accuracy, 78.3%; $p < 0.05$). Their results and those of Moschetta et al., conducted in women regardless of the indication for breast MRI and using the same protocols, resulted in similarly high sensitivity and NPVs.

These four studies evaluated the diagnostic performance of MRI protocols in non-screening populations, in whom a higher number of lesions would be expected compared with screening populations. Nonetheless, the diagnostic performances in the fast and full protocols were equivalent.

With regard to false-negatives in the fast protocol that were detected with the full protocol in the study by Mango et al. [26], eight cancers were missed by at least one of the four readers: five DCIS (grade not specified; mean size, 1.6 cm), two invasive ductal carcinomas (mean size, 0.8 cm), one invasive lobular carcinomas (size, 1.2 cm). Kuhl [29] reported that MRI sensitivity for DCIS detection increases from 80% for low grade to 98% for high grade. In the Moschetta et al. study [27], the eight false-negative cases were mucinous and lobular carcinomas with high signal intensity in T2-weighted images and with mild enhancement mimicking benign lesions. No DCIS was included in their study.

Fast Protocol Combined With Ultrafast Sequences

A perfect breast MRI analysis combines morphologic and kinetic features. Fast protocols can detect nearly all breast cancers, but kinetic features are missing. The acceleration techniques used in ultrafast DCE-MRI sequences shorten acquisition times but maintain high spatial resolution by taking advantage of the redundancy in the acquired image data. Combining a fast protocol with ultrafast sequences promises to simultaneously improve specificity and decrease acquisition time without the need for a full-length protocol to obtain the conventional kinetic curves (Figs. 1, 3–5). Two acquisition acceleration techniques have been used in previous studies: techniques involving the concept of view-sharing and undersampling of the k-space periphery and techniques using parallel imaging methods.

Acquisition acceleration techniques with view-sharing—TWIST (Siemens Healthineers), TRICKS or DISCO (GE Healthcare), TRAQ (Hitachi), and 4D-TRAK (Philips Healthcare) are time-resolved MR angiography (MRA) techniques that use view-sharing and undersampling of the k-space periphery to allow rapid acquisition of multiple images during contrast material inflow (Figs. 3–5).

The first article about an ultrafast sequence was published in 2014 by Mann et al. [30]. They evaluated TWIST acquisitions during contrast material inflow in a conventional

high-resolution dynamic MRI protocol in a retrospective cohort of 160 consecutive patients with 199 enhancing abnormalities (95 benign and 104 malignant). Maximal slopes obtained from ultrafast TWIST sequences allowed discrimination between benign and malignant disease with high accuracy (AUC = 0.829 with sensitivity of 90% and specificity of 67%, cutoff > 6.4%/s for malignancy). Three types of maximal slopes were defined according to the risk of malignancy, as in BI-RADS classification. This simplification provides a considerably higher accuracy than the lengthier BI-RADS curve type analysis (AUC = 0.812 vs 0.692; $p = 0.0061$). However, this study did not perform morphologic analysis of the lesion or evaluate the value that ultrafast analysis added to conventional BI-RADS classification.

In 2017, Mus et al. [31] analyzed the same population as Mann et al. [30] with almost the same ultrafast sequence. They evaluated time to enhancement (TTE) derived from ultrafast TWIST acquisitions to differentiate malignant from benign breast lesions, building on a preliminary study performed by Platel et al. [32]. TTE is defined as the time point at which lesions start to enhance compared with the time point at which the aorta starts to enhance. A TTE cutoff of 12.96 seconds had been found to be the most accurate to distinguish benign from malignant lesions according to a prior study conducted by Boetes et al. [22]. Lesions that became visible before a TTE of 12.96 seconds were classified as malignant; those that enhanced after 12.96 seconds were classified as benign without further morphologic considerations. Lesions that became visible at exactly 12.96 seconds were considered equivocal, and final assessment was based on morphologic characteristics. TTE had a significantly better discriminative ability than did curve type ($p < 0.001$ and $p = 0.026$ for readers 1 and 2, respectively). Once morphologic analysis was included, the sensitivities of the ultrafast sequence and full protocol were equivalent ($p = 0.549$ and $p = 0.344$, respectively). Specificity and diagnostic accuracy were significantly higher for the ultrafast sequence than for the full protocol assessment ($p < 0.001$). These two studies, evaluating semiquantitative kinetic parameters almost regardless of morphologic features, found that early enhancement parameters have a significantly higher accuracy than do conventional late contrast-enhanced curves.

In 2017, Oldrini et al. [28] evaluated the added value of an ultrafast MRI sequence in

Abbreviated Breast MRI Protocols

a fast protocol compared with a full protocol to distinguish benign from malignant lesions in 106 women with histologically proven lesions (58 malignant and 48 benign), regardless of breast MRI indications. The ultrafast acquisition consisted of 12 TRICKS acquisitions during contrast material inflow. The ultrafast protocol consisted of subtraction of MIP images derived from TRICKS scans. The fast protocol consisted of morphologic T2-weighted and unenhanced and contrast-enhanced fat-saturated T1-weighted sequences for a total scan imaging time of 5.8 minutes. For all readers, an abbreviated protocol combining the fast protocol and ultrafast sequence significantly improved specificity to 83.3% versus 70.8% and 60.4% in comparison with the fast protocol alone or full protocol, respectively, without change in sensitivity. By adding an ultrafast sequence to the fast protocol, the readers were able to correctly change the diagnosis in 22.9% (11/48) and 10.4% (5/48) of benign lesions, without missing any malignancy. Thus, regardless of morphologic characteristics, semiquantitative kinetic parameters are useful to increase specificity. Nonetheless, ultrafast sequences alone are not sufficient; they must be added to a fast protocol including morphologic T2-weighted imaging for BI-RADS morphologic characterization.

In another study, Milon et al. [33] found that adding an ultrafast sequence to a fast protocol increased diagnostic performance to reach that of the standard full protocol while reducing acquisition time. This study retrospectively included 120 women (mean age, 55 years old; age range, 28–88 years old) in whom an abnormal, enhancing lesion had been identified with subsequent pathologic analysis (69 benign, seven borderline, and 103 malignant lesions). Two readers classified the lesions according to BI-RADS by first reading images from a fast protocol (T1-weighted, T2-weighted, fat-saturated T1-weighted obtained 2 min after contrast material injection) and then reading images from the standard full protocol (fast with four successive fat-saturated T1-weighted sequences after contrast material injection). Independently, they determined lesion visibility and TTE on the ultrafast sequence. An abbreviated protocol was then devised using data from the ultrafast sequence added to the fast protocol. Early enhancement on the ultrafast sequence (TTE < 31 s) was associated with malignancy with an odds ratio of 5.6 (95% CI, 3.3–20.4; $p < 0.0001$). Adding a

TTE of less than 31 seconds to fast analysis (AUC = 0.826) significantly improved lesion characterization with a diagnostic gain of 10.6% (19/179) of lesions correctly reclassified ($p = 0.0034$) compared with the fast protocol and with a shorter acquisition time (7 min 48 s vs 13 min 54 s).

Acquisition acceleration techniques with parallel imaging—Time-resolved MRA techniques using view-sharing and undersampling of the k-space periphery have a disadvantage in that view-sharing results in temporal blurring and does not allow image reconstruction in other planes. This drawback has given rise to the development of techniques using parallel imaging methods. Sensitivity encoding (SENSE) and array coil spatial sensitivity encoding (also known as ASSET) are among the most widely used parallel imaging methods. These techniques are primarily performed in image space after reconstruction of data from the individual coils. They involve four steps: generating coil sensitivity maps, acquiring partial k-space MRI data, reconstructing partial FOV images from each coil, and unfolding or combining partial FOV images by matrix inversion.

To our knowledge, five studies have evaluated these techniques using parallel imaging methods. They are all pilot studies performed on a small number of lesions with custom protocols. Additional studies are thus required.

In 2016, Abe et al. [34] performed a preliminary study to evaluate the diagnostic utility of an ultrafast sequence compared with a standard acquisition for differentiating benign from malignant lesions in 60 patients with 33 malignant and 29 benign lesions. They developed a custom ultrafast MRI sequence in which whole-breast 3D images were acquired with high temporal resolution (7 s) using higher than usual SENSE acceleration factors and a lower than usual spatial resolution. Ultrafast acquisition was performed during the early phase of contrast enhancement for approximately 1 min after contrast material injection. This acquisition was followed by a standard high-resolution contrast-enhanced T1-weighted acquisition. The IER and the signal enhancement ratio (SER, which is defined as the difference between the signal intensity of an early contrast-enhanced and an unenhanced DCE-MRI series divided by the difference between the signal intensity of a delayed contrast-enhanced and an unenhanced series) were significantly higher in malignant lesions than in benign lesions ($p = 0.001$). Applying 116% as the cutoff enhance-

ment rate on the first TTE ultrafast acquisition, they observed sensitivity of 85%, specificity of 79%, PPV of 82%, and NPV of 82%. ROC curve analysis showed no significant differences between the enhancement rate on the ultrafast sequence and SER or IER on the standard imaging sequence.

In 2016, Pineda et al. [35] evaluated the time of arrival (TOA), defined as the time at which each voxel first satisfies all filter conditions relative to the time of initial arterial enhancement in mammary arteries, to compare its diagnostic utility in differentiating the benign or malignant nature of 18 enhanced lesions. They used another custom protocol that included conventional Fourier sampling as a robust quantitative analysis method to identify rapidly enhanced lesions. Images were acquired at low spatial resolution and relatively high SENSE acceleration factors during the first minute after contrast material injection to produce full, bilateral, fat-suppressed breast images with temporal resolution ranging between 6.2 and 9.9 s. The mean TOA was much shorter for malignant lesions than for benign lesions (18.4 s vs 43.5 s; $p < 0.001$).

In 2018, Jimenez et al. [36] performed a preliminary study in six patients to develop a volumetric imaging technique with 0.8-mm isotropic resolution and 10-second per volume rate to detect and analyze breast lesions in a bilateral DCE-MRI examination. A custom high temporal DCE sequence using both parallel imaging and spatial compressed sensing was designed to create rapid volumetric frame rates during a contrast-enhanced breast examination (vastly undersampled isotropic projection spatial compressed sensing with temporal local low-rank). This reconstruction approach of 3D radial sampling with mask subtraction provides a high-performance imaging technique for characterizing enhancing structures within the breast.

In 2017, two studies were published about the development of new ultrafast sequences. Vreemann et al. [37] evaluated a compressed sensing volumetric interpolated breath-hold examination (VIBE) sequence (CS-VIBE) for ultrafast breast MRI, which enables high spatiotemporal resolution for both dynamic inflow analysis and morphologic evaluation to replace the TWIST sequence, on 31 lesions (five malignant and 26 benign). Imaging time was 1 minutes 31 seconds, and no differences were found in terms of image quality between TWIST and CS-VIBE. Ghosting and infolding artifacts were more frequent ($p < 0.001$)

with the TWIST sequences; breathing and pulsation artifacts (which have lesser effects because they are always outside of the area of interest) were more often seen ($p=0.001$) with the CS-VIBE sequences. The main limit of this new sequence was the time of reconstruction (45 min for each CS-VIBE series on the standard scanner hardware). In the same year, Heacock et al. [38] evaluated a novel multicoil compressed sensing technique with flexible temporal resolution called golden-angle radial sparse parallel (GRASP). This method uses a combination of compressed sensing and parallel imaging to acquire simultaneously high spatial and temporal resolution. The GRASP technique exploits joint multicoil sparsity techniques to allow continuous acquisition of dynamic information before, during, and after contrast agent injection. All 180 biopsy-proven benign and malignant lesions showed good conspicuity on VIBE and GRASP sequences (4.28 ± 0.81 vs 3.65 ± 1.22), with no significant difference in lesion detection ($p=0.248$).

Ongoing Studies

Two clinical trials are ongoing. The first is the DENSE trial, which is a randomized study of breast cancer screening with MRI in women 50–75 years old with extremely dense breast tissue. The main objective is to evaluate if there is a difference in the number of interval cancers detected between the group undergoing MRI and the group not undergoing MRI. The second trial, the EA1141 study, began in 2016 and is comparing an abbreviated breast MRI protocol with digital breast tomosynthesis for breast cancer screening in women with dense breasts. This study is a prospective multicenter diagnostic accuracy study and is sponsored by the Eastern Cooperative Oncology Group and American College of Radiology Imaging Network. Women 40–75 years old with dense breast tissue, defined as mammographic density categories c and d, without breast cancer-related risk factors or symptoms, will undergo digital breast tomosynthesis or an abbreviated breast MRI protocol for 2 consecutive years. The main objective is to compare the detection rate of invasive cancers for these two modalities.

Discussion

Even if fast MRI protocols are somewhat heterogeneous, most studies have found them to have a consistently high sensitivity compared with full breast MRI protocols [4, 12, 13, 21, 24–28], with considerably shorter scan time (7.8 min [range, 3–12.5 min] vs

23.6 min [range, 15–35 min] for fast and full protocols, respectively).

Data from additional ultrafast sequences can provide early enhancement lesion characteristics, which appear to help increase specificity without increasing the acquisition time [30, 31, 33–38]. Nonetheless, conventional high-spatial-resolution sequences appear essential for morphologic analysis, using a T1-weighted sequence acquired after contrast agent injection, and for lesion characterization, for which a T2-weighted sequence could help to downgrade benign lesions. We believe that morphologic analysis must continue to be the first step because a lesion with suspicious morphologic characteristics does not need kinetic analysis to be rated with BI-RADS.

Data from kinetic analysis are useful to refine and help classify lesions with benign morphologic features [33]. An ultrafast sequence can be used to better characterize these lesions using early enhancement characteristics. Many such sequences have been developed, and many semiquantitative parameters have been tested successfully.

Adding an ultrafast sequence to a fast protocol permits both optimal morphologic analysis and lesion enhancement characteristics. In our opinion, an abbreviated breast MRI including ultrafast acquisition could be better and faster than a conventional full protocol [28, 33].

Conclusion

Decreasing acquisition time and improving specificity allows abbreviated breast MRI to satisfy the conditions required for a screening test in a high-risk population, with an additional cancer detection rate of 14.7/1000 and better cost-effectiveness [4]. Abbreviated DCE-MRI with ultrafast imaging might be considered as a screening tool in women with dense breasts who have intermediate risk of developing breast cancer.

References

1. Kuhl CK, Strobel K, Bieling H, Leutner C, Schild HH, Schrading S. Supplemental breast MR imaging screening of women with average risk of breast cancer. *Radiology* 2017; 283:361–370
2. Kuhl CK. Abbreviated breast MRI for screening women with dense breast: the EA1141 trial. *Br J Radiol* 2018; 91:20170441
3. Berg WA. Current status of supplemental screening in dense breasts. *J Clin Oncol* 2016; 34:1840–1843
4. Chen SQ, Huang M, Shen YY, Liu CL, Xu CX. Abbreviated MRI protocols for detecting breast

cancer in women with dense breasts. *Korean J Radiol* 2017; 18:470–475

5. Marshall H, Pham R, Sieck L, Plecha D. Implementing abbreviated MRI screening into a breast imaging practice. *AJR* 2019; 213:234–237
6. Peters NH, Borel Rinkes IH, Zuithoff NP, Mali WP, Moons KG, Peeters PH. Meta-analysis of MR imaging in the diagnosis of breast lesions. *Radiology* 2008; 246:116–124
7. Medeiros LR, Duarte CS, Rosa DD, et al. Accuracy of magnetic resonance in suspicious breast lesions: a systematic quantitative review and meta-analysis. *Breast Cancer Res Treat* 2011; 126:273–285
8. Bennani-Baiti B, Baltzer PA. MR imaging for diagnosis of malignancy in mammographic microcalcifications: a systematic review and meta-analysis. *Radiology* 2017; 283:692–701
9. Kuhl CK, Schild HH, Morakkabati N. Dynamic bilateral contrast-enhanced MR imaging of the breast: trade-off between spatial and temporal resolution. *Radiology* 2005; 236:789–800
10. Kuhl CK, Mielcareck P, Klaschik S, et al. Dynamic breast MR imaging: are signal intensity time course data useful for differential diagnosis of enhancing lesions? *Radiology* 1999; 211:101–110
11. Berg WA, Zhang Z, Lehrer D, et al.; ACRIN 6666 Investigators. Detection of breast cancer with addition of annual screening ultrasound or a single screening MRI to mammography in women with elevated breast cancer risk. *JAMA* 2012; 307:1394–1404
12. Kuhl CK, Schrading S, Strobel K, Schild HH, Hilgers RD, Bieling HB. Abbreviated breast magnetic resonance imaging (MRI): first postcontrast subtracted images and maximum-intensity projection—a novel approach to breast cancer screening with MRI. *J Clin Oncol* 2014; 32:2304–2310
13. Strahle DA, Pathak DR, Sierra A, Saha S, Strahle C, Devisetty K. Systematic development of an abbreviated protocol for screening breast magnetic resonance imaging. *Breast Cancer Res Treat* 2017; 162:283–295
14. Monticciolo DL, Newell MS, Moy L, Niell B, Monsees B, Sickles EA. Breast cancer screening in women at higher-than-average risk: recommendations from the ACR. *J Am Coll Radiol* 2018; 15:408–414
15. Boyd NF, Guo H, Martin LJ, et al. Mammographic density and the risk and detection of breast cancer. *N Engl J Med* 2007; 356:227–236
16. Pollán M, Ascunce N, Ederia M, et al. Mammographic density and risk of breast cancer according to tumor characteristics and mode of detection: a Spanish population-based case-control study. *Breast Cancer Res* 2013; 15:R9
17. Mandelson MT, Oestreicher N, Porter PL, et al. Breast density as a predictor of mammographic de-

Abbreviated Breast MRI Protocols

- tection: comparison of interval- and screen-detected cancers. *J Natl Cancer Inst* 2000; 92:1081–1087
18. Hooley RJ, Greenberg KL, Stackhouse RM, Geisel JL, Butler RS, Philpotts LE. Screening US in patients with mammographically dense breasts: initial experience with Connecticut Public Act 09-41. *Radiology* 2012; 265:59–69
 19. Brem RF, Tabár L, Duffy SW, et al. Assessing improvement in detection of breast cancer with three-dimensional automated breast US in women with dense breast tissue: the SonoInsight Study. *Radiology* 2015; 274:663–673
 20. Kuhl C, Weigel S, Schrading S, et al. Prospective multicenter cohort study to refine management recommendations for women at elevated familial risk of breast cancer: the EVA trial. *J Clin Oncol* 2010; 28:1450–1457
 21. Heacock L, Melsaether AN, Heller SL, et al. Evaluation of a known breast cancer using an abbreviated breast MRI protocol: correlation of imaging characteristics and pathology with lesion detection and conspicuity. *Eur J Radiol* 2016; 85:815–823
 22. Boetes C, Barentsz JO, Mus RD, et al. MR characterization of suspicious breast lesions with a gadolinium-enhanced turboFLASH subtraction technique. *Radiology* 1994; 193:777–781
 23. Sardanelli F, Rescinito G, Giordano GD, Calabrese M, Parodi RC. MR dynamic enhancement of breast lesions: high temporal resolution during the first-minute versus eight-minute study. *J Comput Assist Tomogr* 2000; 24:724–731
 24. Harvey SC, Di Carlo PA, Lee B, Obadina E, Sippo D, Mullen L. An abbreviated protocol for high-risk screening breast MRI saves time and resources. *J Am Coll Radiol* 2016; 13:374–380
 25. Panigrahi B, Mullen L, Falomo E, Panigrahi B, Harvey S. An abbreviated protocol for high-risk screening breast magnetic resonance imaging: impact on performance metrics and BI-RADS assessment. *Acad Radiol* 2017; 24:1132–1138
 26. Mango VL, Morris EA, David Dershaw D, et al. Abbreviated protocol for breast MRI: are multiple sequences needed for cancer detection? *Eur J Radiol* 2015; 84:65–70
 27. Moschetta M, Telegrafo M, Rella L, Stabile Ianora AA, Angelelli G. Abbreviated combined MR protocol: a new faster strategy for characterizing breast lesions. *Clin Breast Cancer* 2016; 16:207–211
 28. Oldrini G, Fedida B, Poujol J, et al. Abbreviated breast magnetic resonance protocol: value of high-resolution temporal dynamic sequence to improve lesion characterization. *Eur J Radiol* 2017; 95:177–185
 29. Kuhl CK. Why do purely intraductal cancers enhance on breast MR images? *Radiology* 2009; 253:281–283
 30. Mann RM, Mus RD, van Zelst J, Geppert C, Karssemeijer N, Platel B. A novel approach to contrast-enhanced breast magnetic resonance imaging for screening: high-resolution ultrafast dynamic imaging. *Invest Radiol* 2014; 49:579–585
 31. Mus RD, Borelli C, Bult P, et al. Time to enhancement derived from ultrafast breast MRI as a novel parameter to discriminate benign from malignant breast lesions. *Eur J Radiol* 2017; 89:90–96
 32. Platel B, Mus R, Welte T, Karssemeijer N, Mann R. Automated characterization of breast lesions imaged with an ultrafast DCE-MR protocol. *IEEE Trans Med Imaging* 2014; 33:225–232
 33. Milon A, Vande Perre S, Poujol J, et al. Abbreviated breast MRI combining FAST protocol and high temporal resolution (HTR) dynamic contrast enhanced (DCE) sequence. *Eur J Radiol* 2019; 117:199–208
 34. Abe H, Mori N, Tsuchiya K, et al. Kinetic analysis of benign and malignant breast lesions with ultrafast dynamic contrast-enhanced MRI: comparison with standard kinetic assessment. *AJR* 2016; 207:1159–1166
 35. Pineda FD, Medved M, Wang S, et al. Ultrafast bilateral DCE-MRI of the breast with conventional Fourier sampling: preliminary evaluation of semi-quantitative analysis. *Acad Radiol* 2016; 23:1137–1144
 36. Jimenez JE, Strigel RM, Johnson KM, Henze Bancroft LC, Reeder SB, Block WF. Feasibility of high spatiotemporal resolution for an abbreviated 3D radial breast MRI protocol. *Magn Reson Med* 2018; 80:1452–1466
 37. Vreemann S, Rodriguez-Ruiz A, Nickel D, et al. Compressed sensing for breast MRI: resolving the trade-off between spatial and temporal resolution. *Invest Radiol* 2017; 52:574–582
 38. Heacock L, Gao Y, Heller SL, et al. Comparison of conventional DCE-MRI and a novel golden-angle radial multicoil compressed sensing method for the evaluation of breast lesion conspicuity. *J Magn Reson Imaging* 2017; 45:1746–1752

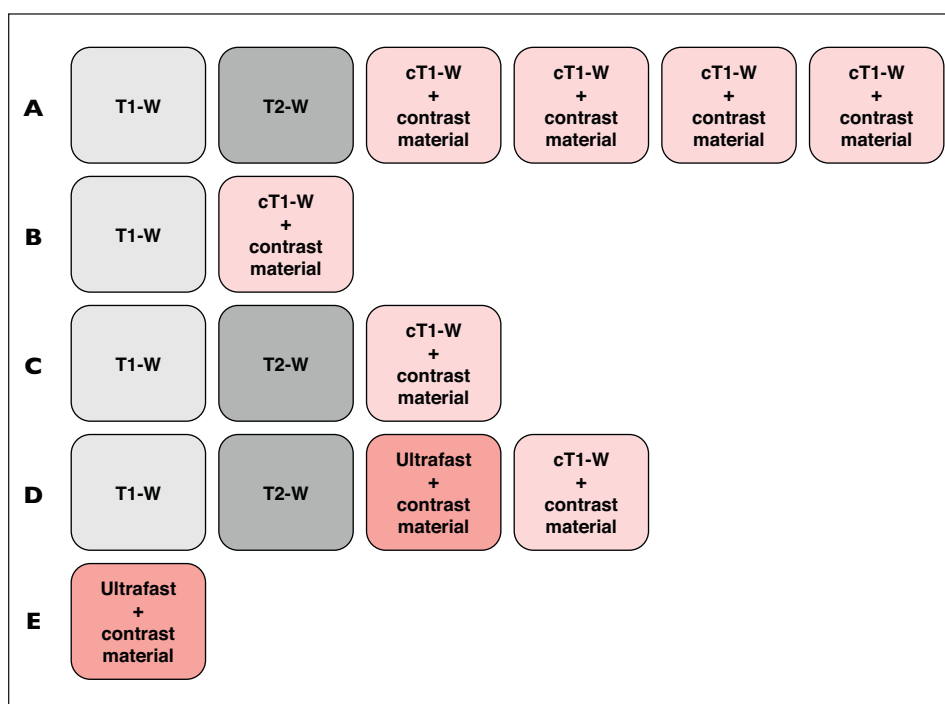


Fig. 1—Breast MRI protocols.
A, Full breast MRI protocol consists of at least one T1-weighted (T1-W) and T2-weighted (T2-W) sequence before contrast material injection and several T1-weighted conventional high-spatial-resolution T1-weighted (cT1-W) sequences acquired to build enhancement curves.
B, Example of fast protocol that consists of only T1-weighted conventional high-spatial-resolution sequence before and after contrast administration. This protocol corresponds to type studied by Kuhl et al. [12] and Mango et al. [26].
C, Example of fast protocol that consists of T2-weighted and T1-weighted conventional high-spatial-resolution sequence before and after contrast administration. This protocol corresponds to type studied by Heacock et al. [21] and Moschetta et al. [27].
D, Example of abbreviated protocol that is composed of fast protocol to which ultrafast sequence is added to allow early enhancement parameter analysis. This protocol corresponds to type studied by Oldrini et al. [28] and Milon et al. [33].
E, Example of protocol with only ultrafast sequence, which allows early enhancement parameter analysis but not morphologic analysis. This protocol corresponds to type studied by Mann et al. [30] and Mus et al. [31].

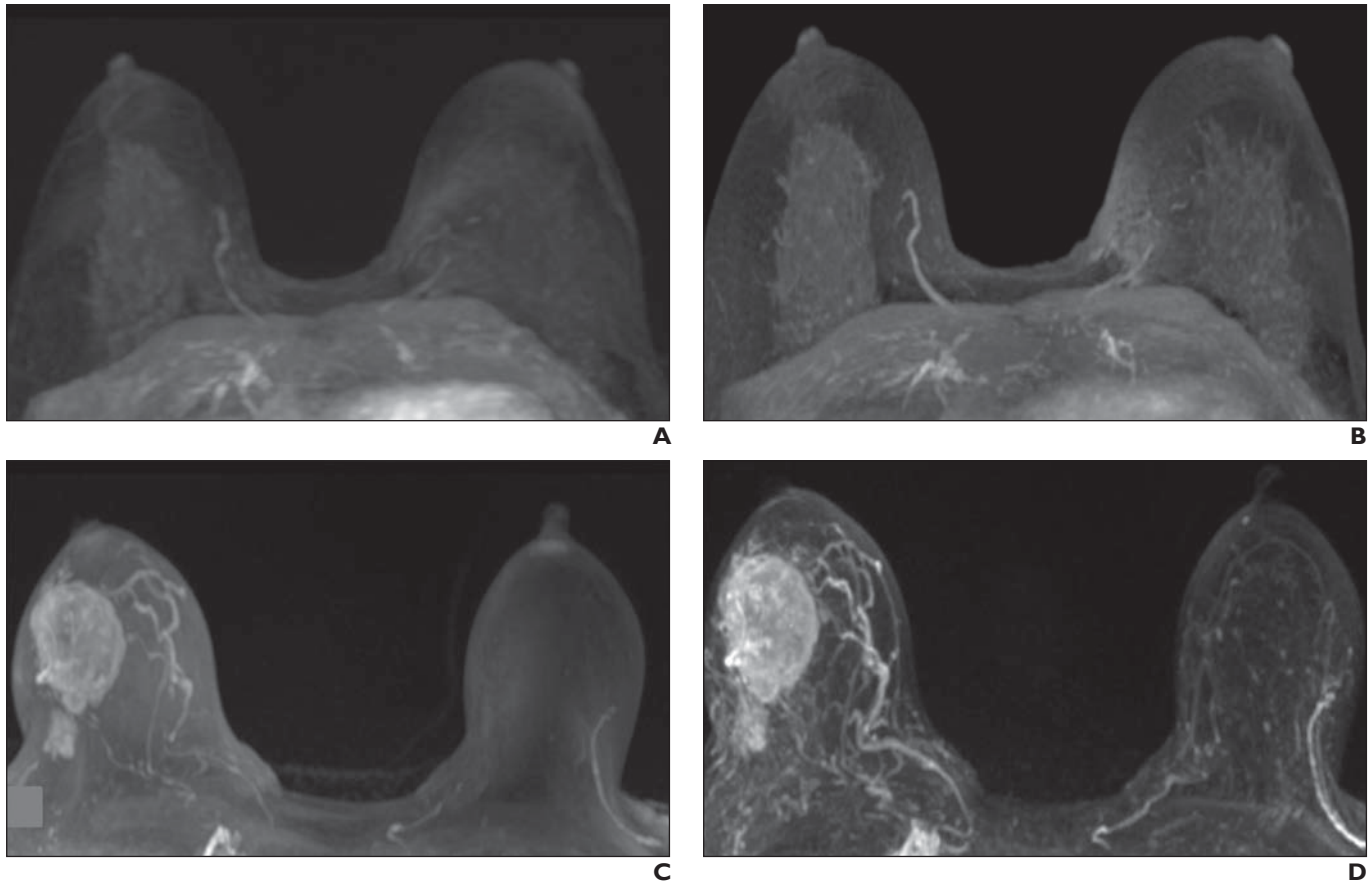


Fig. 2—Maximum-intensity-projection (MIP) image analysis built on subtracted images of ultrafast sequence and subtracted images of conventional dynamic contrast-enhanced (DCE)-MRI.
A and B, 42-year-old woman at high risk for breast cancer undergoing MRI for cancer screening. Findings are negative on subtracted MIP image of ultrafast sequence (**A**) and on conventional T1-weighted DCE-MR image (**B**).
C and D, 38-year-old woman undergoing MRI to stage malignant lesion in right breast (invasive ductal carcinoma, grade 3). Findings are positive on subtracted MIP image of ultrafast sequence (**C**) and on conventional T1-weighted DCE MR-image (**D**).

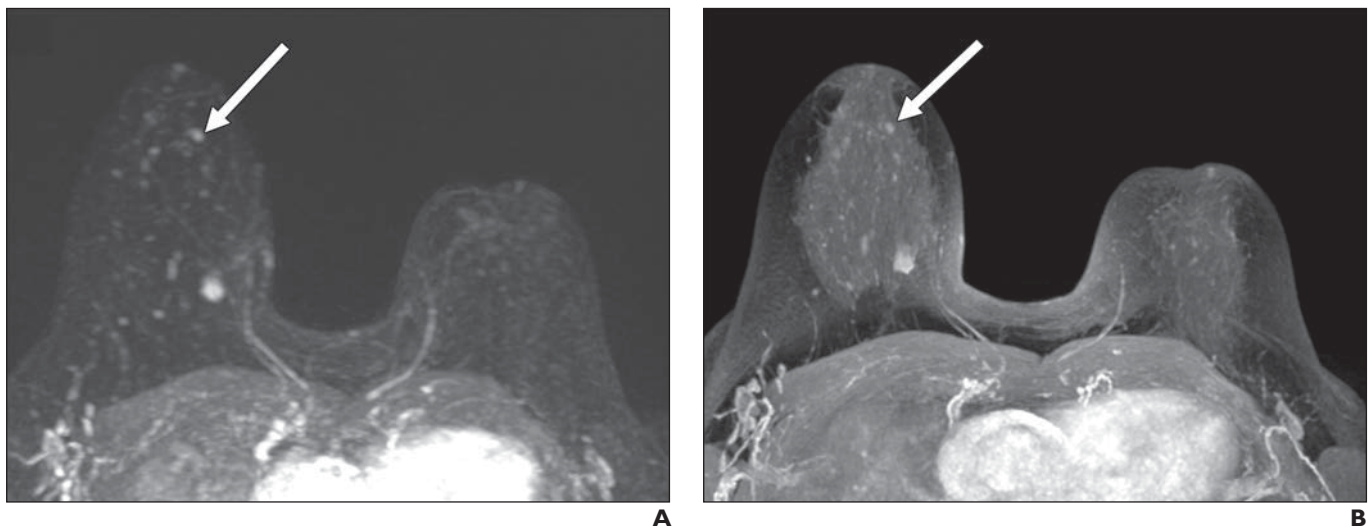


Fig. 3—Steps for analyzing breast MRI including ultrafast sequence. 70-year-old woman who underwent breast MRI for staging of mass (lobular carcinoma of superior and medial quadrant of right breast). She had undergone tumorectomy for contralateral breast carcinoma 4 years before.
A and B, In first step, reader must determine if lesion is visible on subtracted maximum-intensity-projection image of ultrafast sequence (**A**) and conventional T1-weighted dynamic contrast-enhanced MR (DCE-MR) image (**B**). Additional subcentimeter lesion in same breast also needs to be analyzed (*arrow*).

(Fig. 3 continues on next page)

Abbreviated Breast MRI Protocols

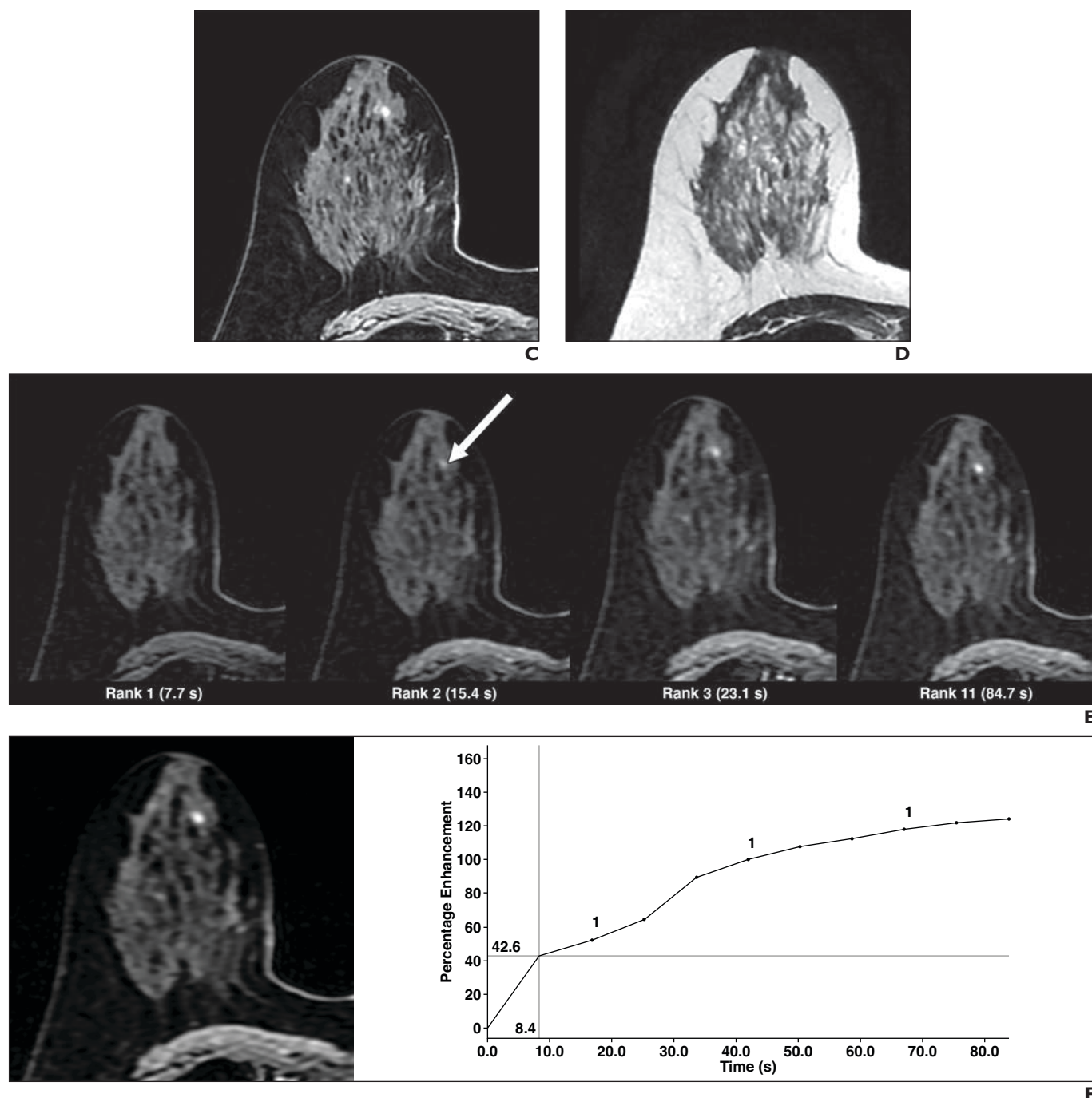


Fig. 3 (continued)—Steps for analyzing breast MRI including ultrafast sequence. 70-year-old woman who underwent breast MRI for staging of mass (lobular carcinoma of superior and medial quadrant of right breast). She had undergone tumorectomy for contralateral breast carcinoma 4 years before. **C** and **D**. In second step, reader must determine if lesion displays suspicious morphologic features (e.g., irregular shape, irregular or spiculated margins). Morphologic features are better analyzed on conventional contrast-enhanced high-spatial-resolution T1- (**C**) or T2-weighted (**D**) MRI. This lesion is round and margins are circumscribed, which means that morphologic features are not suspicious. Lesion would be classified BI-RADS category 3 or 4 depending on enhancement characteristics. **E–G**. Third step consists of kinetic analysis that is required for correct BI-RADS classification of lesion presenting benign morphologic features. Ultrafast sequence reveals very early lesion enhancement (depending on temporal resolution chosen). This lesion (*arrow*, **E**) is first visible on rank 2 of ultrafast sequence (**E**), which is DISCO sequence (GE Healthcare; techniques using view-sharing and undersampling k-space periphery) with temporal resolution of 7.7 s for each rank, which means enhancement within first 15 s after contrast material injection. Reader may draw ROI within lesion for ultrafast sequence (**F**) or conventional DCE-MR sequence (**G**). Early enhancement of lesion on ultrafast sequence is suspicious. Lesion presents conventional enhancement according to time–signal intensity curve type 2. Biopsy showed it to be invasive ductal carcinoma (grade 2).

(Fig. 3 continues on next page)

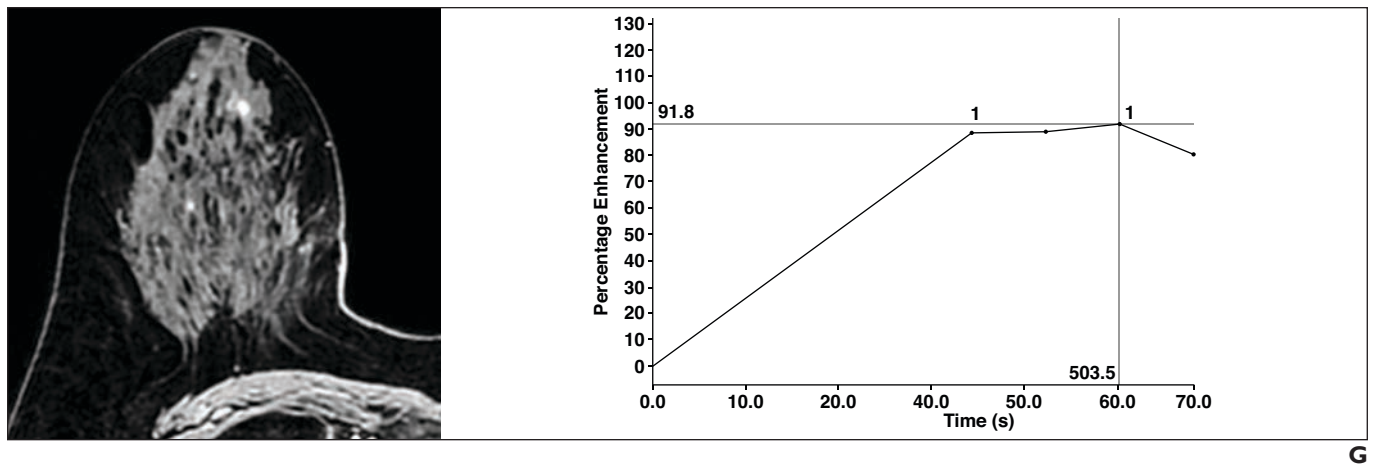
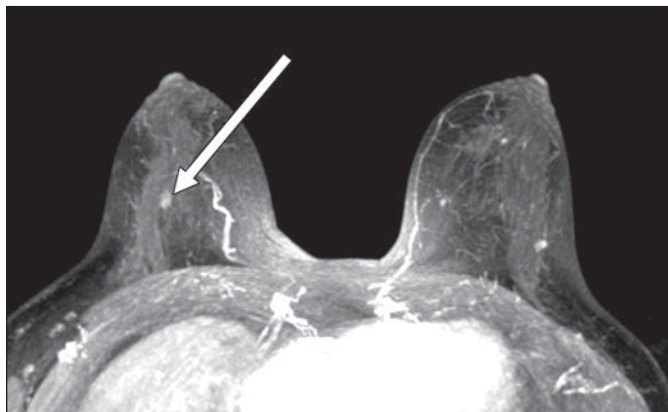


Fig. 3 (continued)—Steps for analyzing breast MRI including ultrafast sequence. 70-year-old woman who underwent breast MRI for staging of mass (lobular carcinoma of superior and medial quadrant of right breast). She had undergone tumorectomy for contralateral breast carcinoma 4 years before. **E–G**, Third step consists of kinetic analysis that is required for correct BI-RADS classification of lesion presenting benign morphologic features. Ultrafast sequence reveals very early lesion enhancement (depending on temporal resolution chosen). This lesion (*arrow*, **E**) is first visible on rank 2 of ultrafast sequence (**E**), which is DISCO sequence (GE Healthcare; techniques using view-sharing and undersampling k-space periphery) with temporal resolution of 7.7 s for each rank, which means enhancement within first 15 s after contrast material injection. Reader may draw ROI within lesion for ultrafast sequence (**F**) or conventional DCE-MR sequence (**G**). Early enhancement of lesion on ultrafast sequence is suspicious. Lesion presents conventional enhancement according to time–signal intensity curve type 2. Biopsy showed it to be invasive ductal carcinoma (grade 2).

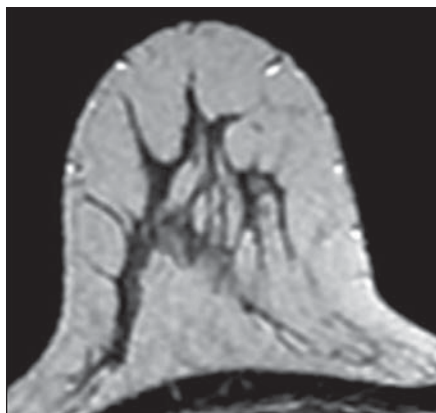


A

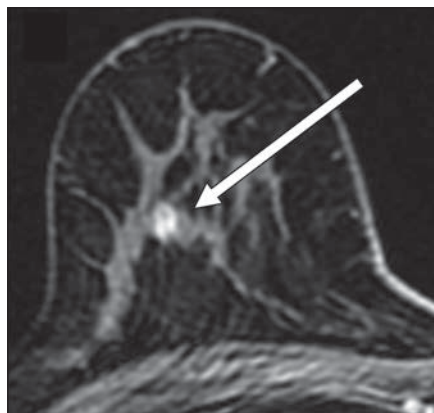
Fig. 4—39-year-old woman at high risk for breast cancer who underwent MRI for screening.

A, Indeterminate small lesion (*arrow*) was detected on right breast on conventional T1-weighted maximum-intensity-projection (MIP) analysis. **B–D**, Lesion was isointense compared with fibroglandular tissue on T2-weighted MR image (**B**) and had benign morphologic features on contrast-enhanced T1-weighted conventional sequences with (**C**) and without (**D**) fat saturation (*arrow*, **C** and **D**).

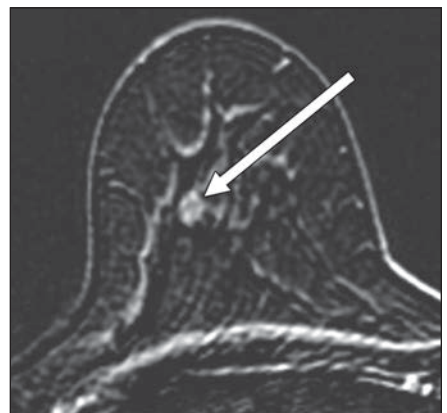
(Fig. 4 continues on next page)



B



C



D

Abbreviated Breast MRI Protocols

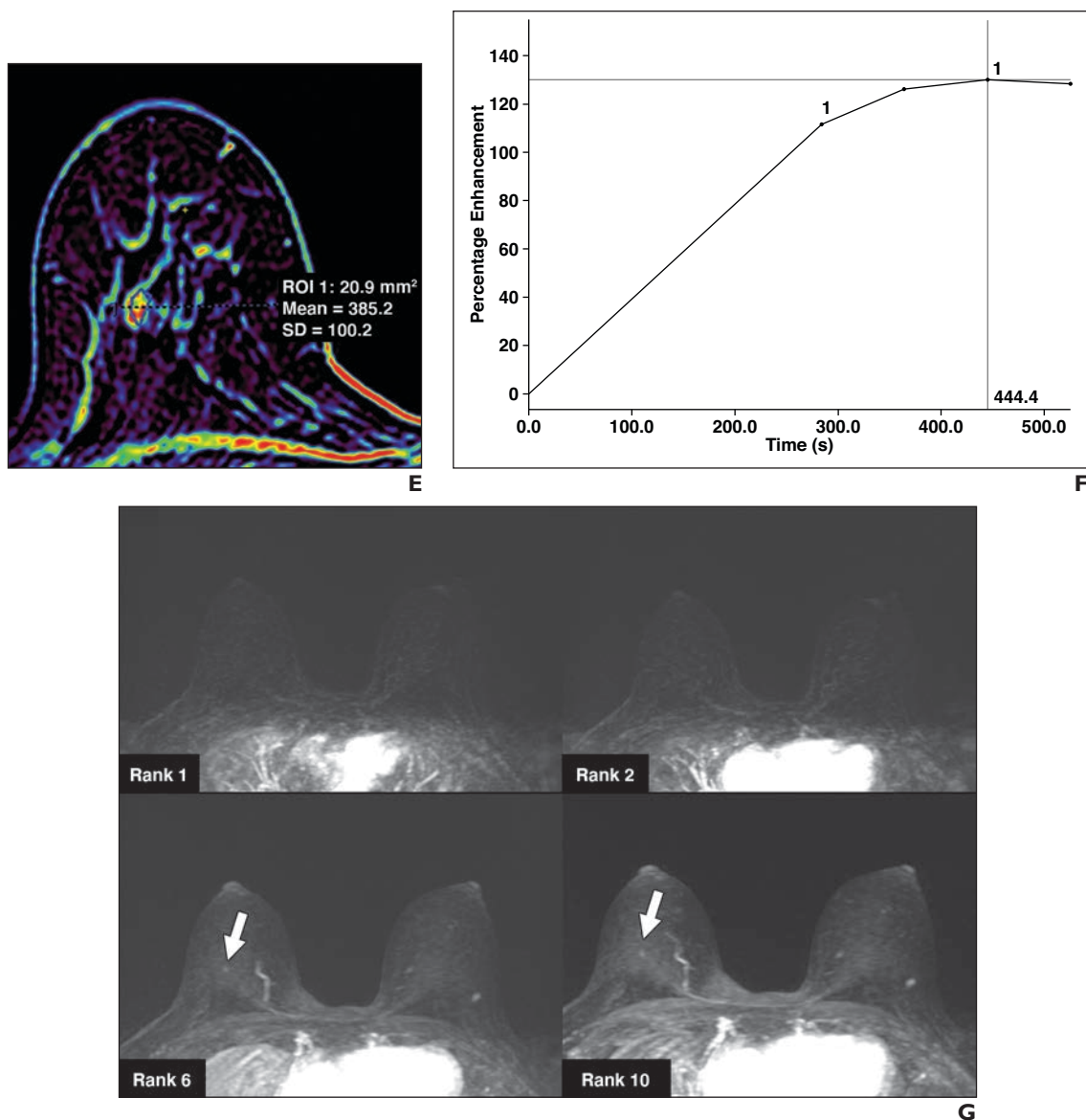


Fig. 4 (continued)—39-year-old woman at high risk for breast cancer who underwent MRI for screening. **E** and **F**, ROI is drawn on parametric positive enhancement integral map (**E**) derived from several contrast-enhanced T1-weighted conventional sequences to build conventional enhancement curve (**F**), which for this case is time-signal intensity curve type 2. Instead of conventional enhancement curves that require long acquisition time, ultrafast sequence (less time consuming) acquired immediately after contrast material injection tends to provide sufficient information to allow analysis of whether lesion has suspicious or nonsuspicious enhancement. **G–I**, Lesion (arrows, **G** and **H**) became visible from 46 seconds (rank 6) on ultrafast MIP (**G**) or native (**H**) images, meaning late nonsuspicious enhancement, which is illustrated on enhancement curve (**I**) extracted from ROI drawn on ultrafast sequence. This case illustrates that there is no need to acquire late contrast-enhanced conventional T1-weighted sequences if enhancement parameters can be obtained by ultrafast sequence, which is much less time consuming (7 min 48 s vs 13 min 54 s). Biopsy of lesion revealed fibroadenoma.

(Fig. 4 continues on next page)

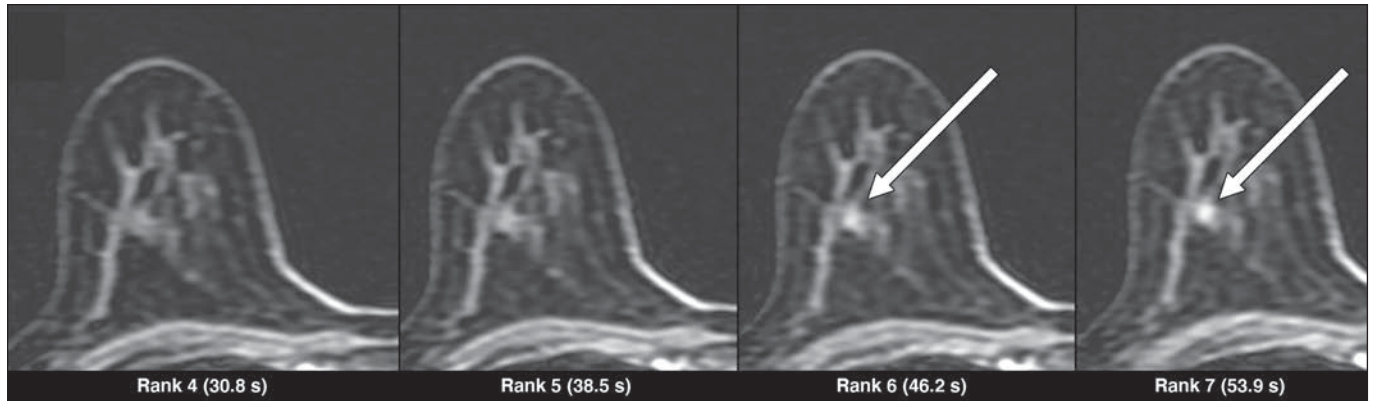


Fig. 4 (continued)—39-year-old woman at high risk for breast cancer who underwent MRI for screening. **G–I**, Lesion (arrows, **G** and **H**) became visible from 46 seconds (rank 6) on ultrafast MIP (**G**) or native (**H**) images, meaning late nonsuspicious enhancement, which is illustrated on enhancement curve (**I**) extracted from ROI drawn on ultrafast sequence. This case illustrates that there is no need to acquire late contrast-enhanced conventional T1-weighted sequences if enhancement parameters can be obtained by ultrafast sequence, which is much less time consuming (7 min 48 s vs 13 min 54 s). Biopsy of lesion revealed fibroadenoma.

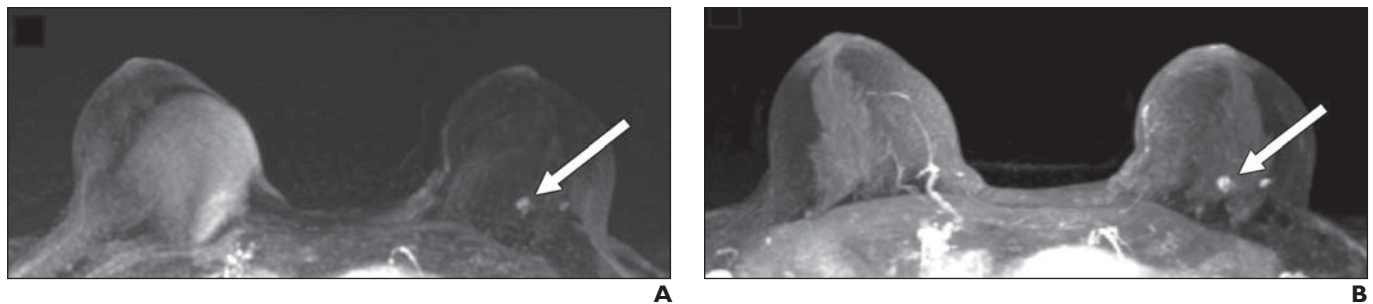
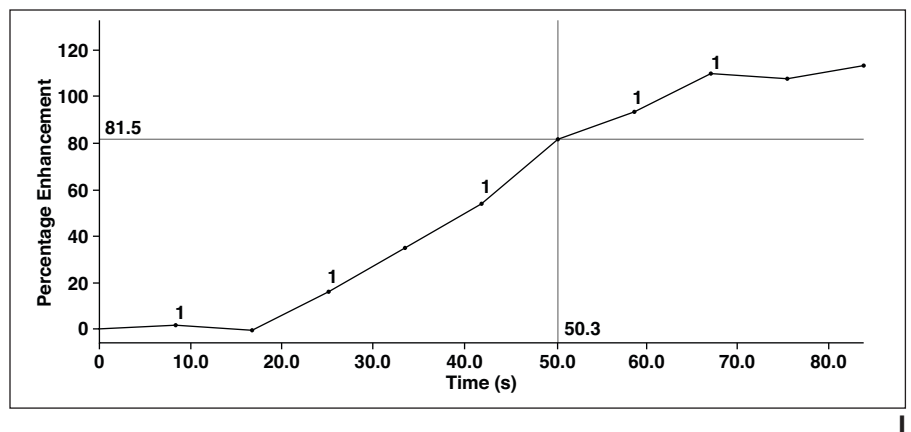


Fig. 5—45-year-old woman at high risk for breast cancer referred for screening. In this fast protocol including ultrafast sequence, reader needs to classify lesion with T2-weighted sequence, T1-weighted conventional high-spatial-resolution sequence, first T1-weighted fat-saturated conventional sequence after contrast material injection, ultrafast DISCO sequence (GE Healthcare; technique uses view-sharing and undersampling of k-space periphery) with temporal resolution of 7.7 s for each rank. Postprocessing images derived from T1-weighted conventional sequence and ultrafast sequence were also analyzed. **A** and **B**, Readers detected abnormal enhancement (arrow) on subtracted maximum-intensity-projection image of ultrafast sequence (**A**) and conventional T1-weighted sequence (**B**).

(Fig. 5 continues on next page)

Abbreviated Breast MRI Protocols

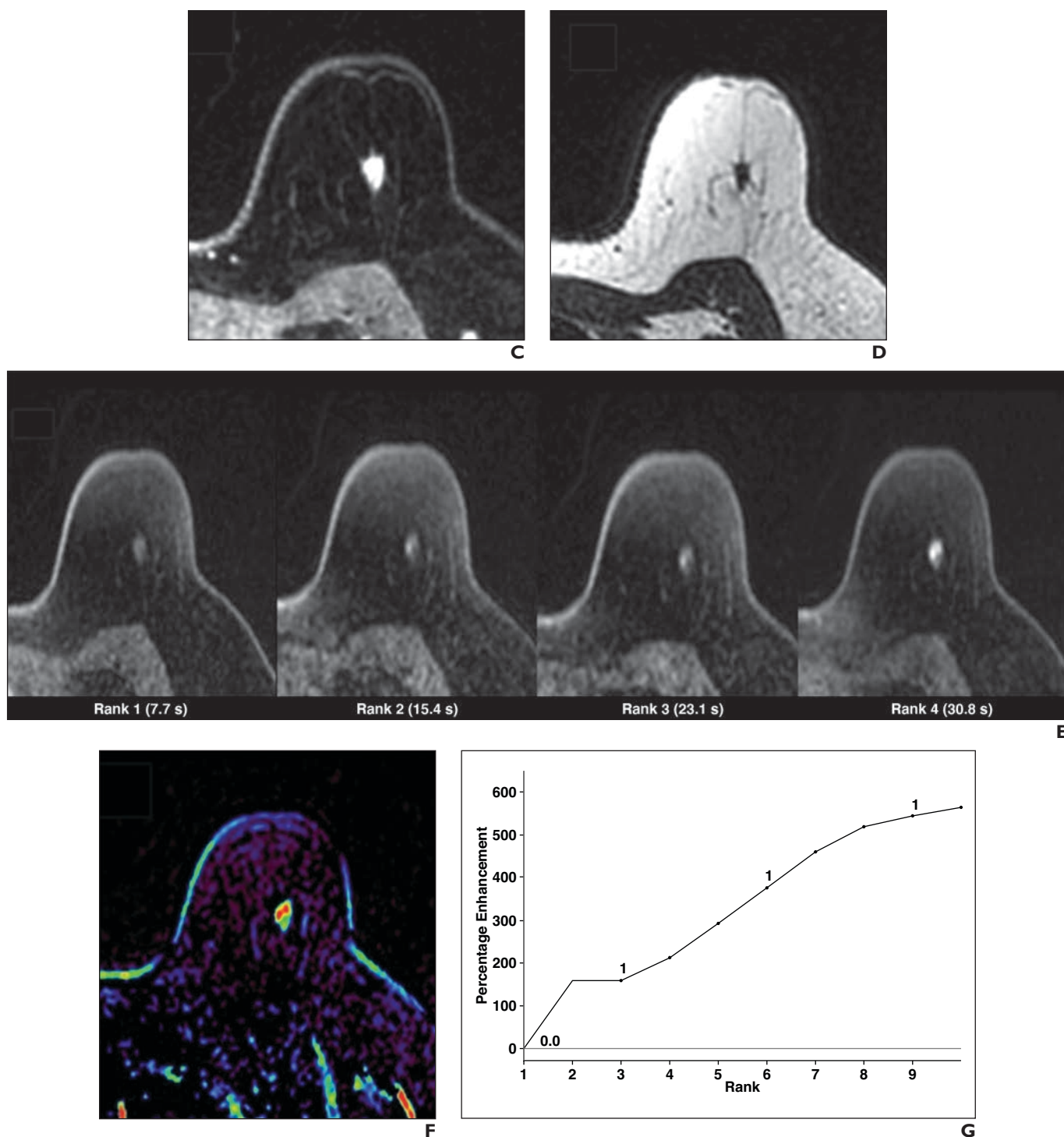


Fig. 5 (continued)—45-year-old woman at high risk for breast cancer referred for screening. In this fast protocol including ultrafast sequence, reader needs to classify lesion with T2-weighted sequence, T1-weighted conventional high-spatial-resolution sequence, first T1-weighted fat-saturated conventional sequence after contrast material injection, ultrafast DISCO sequence (GE Healthcare; technique uses view-sharing and undersampling of k-space periphery) with temporal resolution of 7.7 s for each rank. Postprocessing images derived from T1-weighted conventional sequence and ultrafast sequence were also analyzed.

C and D, Morphologic features were analyzed on conventional contrast-enhanced T1-weighted (**C**) and T2-weighted (**D**) sequences. This small lesion has oval shape and irregular margins, so it would be classified at least BI-RADS category 4b and require biopsy.

E–G, Readers analyzed lesion enhancement derived from ultrafast analysis to determine when lesion first become visible on different ultrafast acquisitions (**E**). Lesion starts to enhance on rank 2 (within first 15 s), as can be seen on graph (**G**) derived from ultrafast sequence after drawing ROI on native ultrafast image (on rank on which lesion is easily visible) or on parametric positive enhancement integral map (**F**) derived from ultrafast sequence. Early enhancement confirms that lesion is suspicious. Second-look sonography and percutaneous biopsy revealed invasive lobular carcinoma.